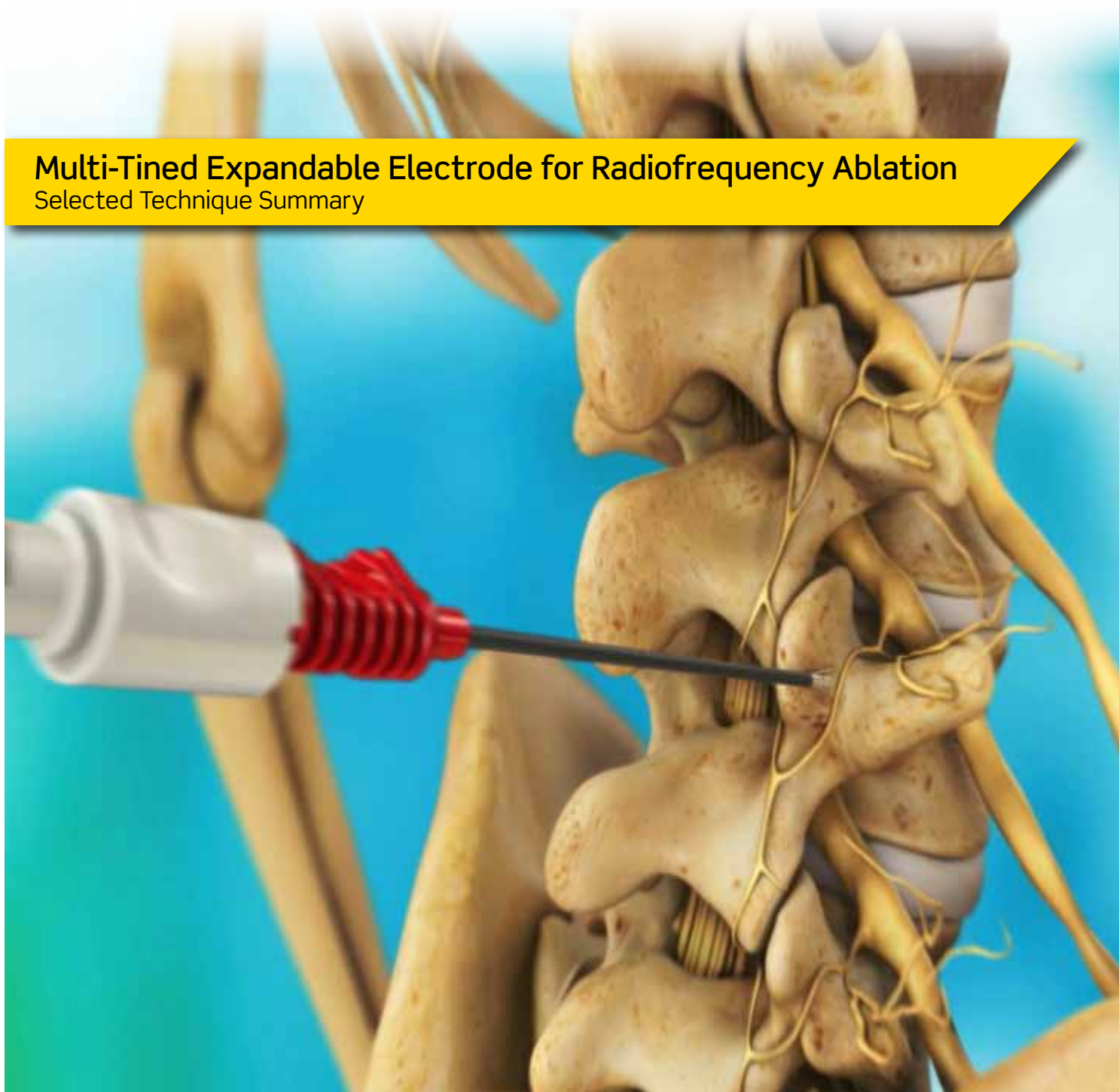


## Multi-Tined Expandable Electrode for Radiofrequency Ablation

Selected Technique Summary



## CONTENTS

- 3 Rationale for the technology
- 4 Scientific validation
- 5 The device key features
- 6 Introductory technical guidelines

### SPINAL APPLICATIONS

- 6 Dorsal sacroiliac joint RF denervation - “Continuum procedure”
- 10 Lumbar medial branch neurotomy
- 11 Down-the-beam technique [L1-L4 Medial Branches]
- 13 Down-the-beam technique [L5 Dorsal Ramus]
- 14 Thoracic medial branch neurotomy
- 17 Cervical medial branch neurotomy [Third occipital nerve (TON)/C3]
- 18 Cervical medial branch neurotomy [C4, C5]
- 19 Cervical medial branch neurotomy [C6, C7]
- 19 Cervical medial branch neurotomy [C8]

### SYMPATHETIC NERVOUS SYSTEM

- 22 Thoracic sympathectomy
- 23 Lumbar sympathectomy

### MAJOR PERIPHERAL JOINTS

- 24 Obturator articular branches to hip joint
- 27 Femoral articular branches
- 28 Genicular nerve ablation to knee joint
- 29 Reading list

## RATIONALE FOR THE TECHNOLOGY

Optimal patient outcome following radiofrequency (RF) thermal neurotomy demands exacting patient selection and generation of a RF lesion fully encompassing sufficient length of the pain-transmitting pathway. Relevant neuroanatomy, and the appropriate targets for RF lesioning have been well described, however to date, inherent limitations in conventional electrode technology have compromised universally positive outcomes.

Over the past 20 years significant time and effort has been devoted to developing strategies, and teaching technically intensive techniques to compensate for the insufficient lesion created by the standard RF electrode. Scant attention has been devoted to improving the technology. Nimbus Concepts was founded to advance RF electrode technology with the goal of broadly improving patient outcomes.

The Nimbus Multi-Tined Expandable Electrode (Nimbus MEE) uses deployable tines as a simple and robust solution for creating optimal lesion geometry in terms of size and shape. The size and shape of the Nimbus MEE lesion was rationally derived from current anatomical knowledge, and allows for consistent, safe, and thorough target tissue coagulation via technically simple, and easily mastered techniques, as illustrated in this guide.

## SCIENTIFIC VALIDATION

The scientific basis for the safety and efficacy of the Nimbus MEE was established in pre-clinical, and early clinical testing. The following investigations were accomplished:

1. **Quantitative lesion analysis:** The size and shape of the lesion was evaluated in various tissue types including egg white, muscle tissue, and organ tissue. The geometry of the lesion was predictable and highly reproducible.
2. **Qualitative lesion analysis:** The evolution of the lesion was observed under thermography to monitor for consistency and symmetry. The Nimbus MEE lesion progressed smoothly and without asymmetry in all instances.
3. **In-Vivo Temperature mapping:** Temperature mapping with a discrete thermocouple was executed during medial branch neurotomy. Ex-vivo lesion data were confirmed.
4. **MRI scan:** Tissue changes pursuant to radiofrequency lesioning were evaluated in the cervical, lumbar and sacral regions. The findings were consistent with the ex-vivo data supporting a safe, but sufficient lesion volume.
5. **Ultrasound (bipolar):** Discernible and contiguous changes in tissue ultrasound response were noted between devices activated in a bipolar configuration.
6. **Paraspinal Electromyography:** Denervation of relevant cervical and lumbar multifidi was documented in initial cohort of lumbar and cervical medial branch neurotomy patients.

Of the above-mentioned investigations, only the quantitative lesion analysis (chicken breast coagulation) is routinely reported in the testing of RF electrodes. The Nimbus MEE testing protocol establishes a new and unique benchmark for evaluating radio-frequency devices.



Figure 1 - Lesion diameter axial slice.

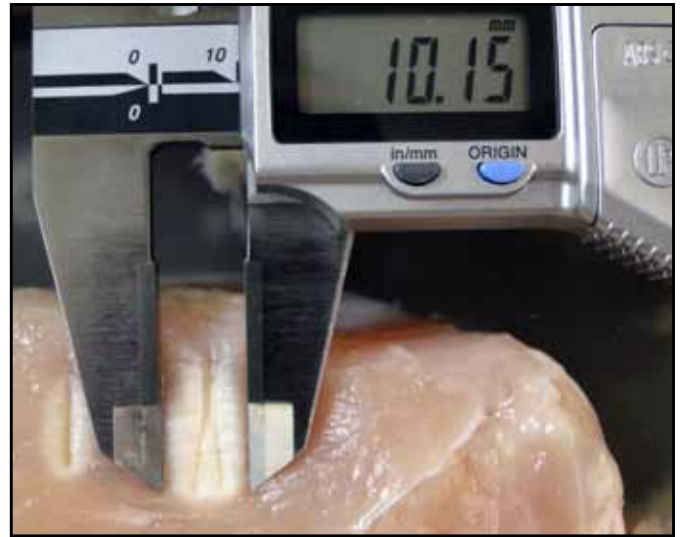

Figure 2 - Length of lesion at distal tip = footprint (20 gauge comparison).

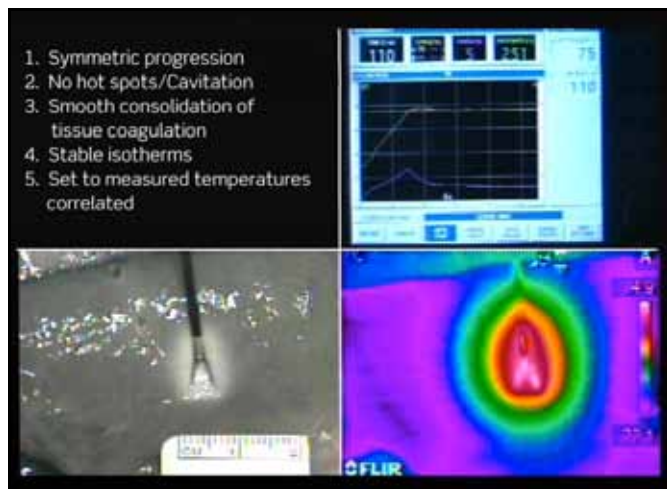


Figure 3 - Lesion analysis with thermography and visible tissue change.

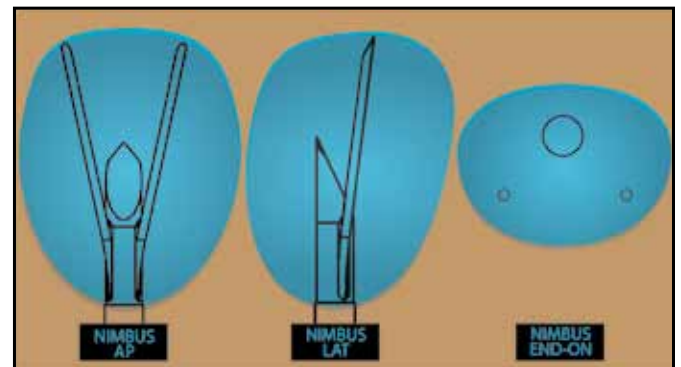



Figure 4 - 3-view summary of lesion geometry.

## THE DEVICE KEY FEATURES

### Design

The device consists of five main components:

1. **Spin collar:** helical, clockwise rotation of the spin collar deploys tines, and secures them in place with a locking mechanism when completely deployed. Hub is sealed after spin collar is clicked into place allowing for fluid injection. Counter-clockwise rotation retracts tines into tip for repositioning or removal of device.
2. **Main hub:** ergonomic triangular design provides a familiar pencil grip. Stripe indicator on color-coded hub indicates the direction of tine deflection.
3. **Central cannula:** main shaft containing continuous filament and lumen for injection purposes. Bending of cannula is not required for any technique, and should be avoided.
4. **Tip:** metal infusion-molding production process employed for consistent quality. Bezel shaped for ease of navigation with occluded non-coring distal tip.
5. **Dual deployable tines:** stable and durable tines are the distal tips of continuous filament so they never dislodge or fracture, and provide excellent electrical interface with thermocouple probe.



### Features

- >> Lesion produced is elongate spheroid with 10 mm axial diameter, and 12 mm length. Perpendicular placement will treat 10 mm of target tissue.
- >> Lesion offset from central axis of cannula allows directed lesioning of target to better spare collateral tissue.
- >> Capable of meaningful motor and sensory stimulation.
- >> Contains lumen for injection with tines deployed.
- >> Robust, simple, mechanical design compatible with most existing RF generators.
- >> No additional equipment requirement.

## INTRODUCTORY TECHNICAL GUIDELINES

This technique guide illustrates general approaches to various targets commonly encountered in pain management practice. The information contained herein is intended to serve as an advanced guide for practitioners experienced in the conduct of basic RF procedures, not as a substitute for necessary training in the discipline.

The techniques and electrode positions illustrated are rationally derived from the basic science benchmarking of Nimbus lesion geometry referenced to known anatomy. In developing these techniques we have drawn from the existing literature while taking advantage of the unique Nimbus MEE lesion geometry to offer simplified approaches where possible. The goal in each instance is to guide a safe, effective procedure that produces thorough ablation of the nociceptive pathway while minimizing tissue trauma, x-ray exposure, and operative time. The goal in each instance is to guide a safe, effective procedure that produces thorough ablation of the nociceptive pathway while minimizing tissue trauma, x-ray exposure, and operative time.

This development of this guide was preceded by hundreds of cases safely and successfully performed in the U.S., Canada, and Europe, and was informed by extensive input from highly experienced physicians. It is anticipated that these techniques will be further refined and evolve as practitioners gain experience with the Nimbus MEE.

## SPINAL APPLICATIONS

### DORSAL SACROILIAC JOINT RF DENERVATION – “CONTINUUM PROCEDURE”

**BACKGROUND:** Increasing awareness of sacroiliac joint pain has led to the need for a simple, economical, and reliable technique for dorsal SIJ RF denervation. The highly variable dorsal innervation of the SIJ requires a robust technique to reliably lesion the lateral branches of S1, S2, and S3, as well as the dorsal ramus of L5 when present. An ideal lesion extends from the base of the S1 SAP and extends to a point lateral to the S3 PSFA. The lesion should be positioned <10 mm lateral to the S1-S3 PFSA and is approximately 10 mm wide and 10 mm deep to encompass variable anatomy and create a wide enough interruption in the lateral branch to support durable clinical response.

The Nimbus MEE was tested ex-vivo in a bipolar configuration and consistently produced a contiguous lesion of the necessary dimensions with a 20 mm electrode separation and a heating protocol of 30-second ramp followed by 120 seconds at 80 C. To ensure in-vivo consistency, the optimal electrode gap recommended is approximately 15 mm and optimal total lesion time is 180 seconds at 90 C.



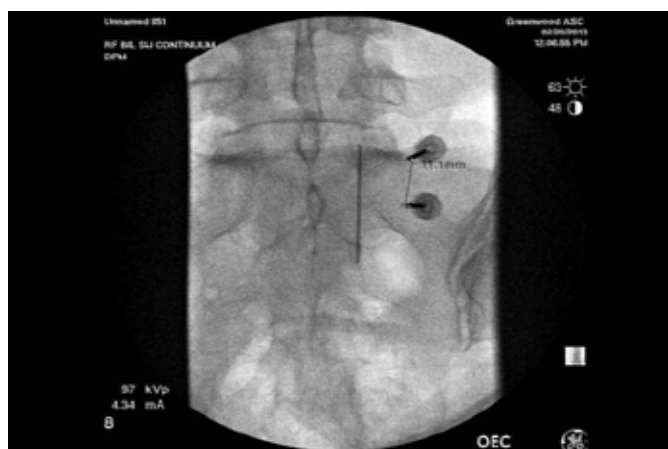


Figure 6 - Contiguous lesion resulting from bipolar activation with 20 mm gap between electrodes.

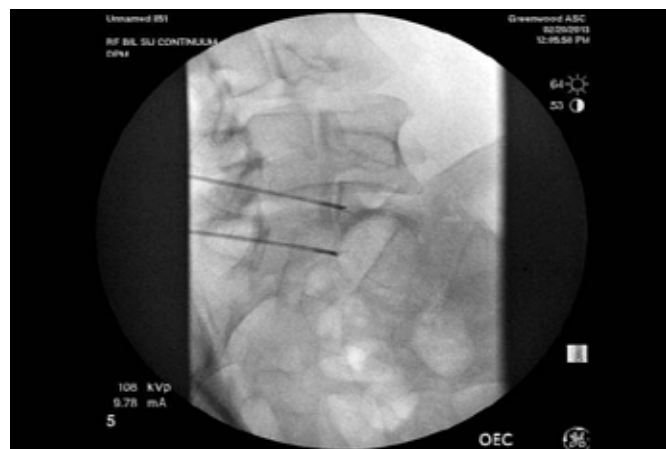
#### **PROCEDURE (Bipolar mode)**

1. Consider patient bowel prep night before to improve visualization.
2. Consider caudal anesthetic or IV sedation.
3. Image sacrum from AP view with craniocaudal adjustment optimized for L5S1 intervertebral disc space.
4. In patients without L5-S1 fusion identify groove at base of S1 SAP and sacral ala.
5. Identify the lateral foraminal walls of the S1, S2, and S3 spinal foramen. The posterior sacral foramenal aperture (PFSA) for the relevant spinal nerve is typically at the ‘inflection’ point of these lines.
6. Electrode #1
  - a. Identify the groove between sacral ala and S1 superior articular process (SAP).
  - b. Anesthetize skin over target. Deeper local indicated if sedation/caudal not used.
  - c. Gripping the central hub (colored), advance the Nimbus MEE down the beam to the posterior aspect of the groove at the base of S1 SAP.
  - d. Confirm placement in groove with ipsilateral oblique view.

7. Electrode #2
  - a. Identify a position approximately 15 mm caudal to initial electrode, slightly lateral to a craniocaudal line connecting the inflection points of the S1, S2, and S3 lateral foramenal walls.
  - b. Anesthetize skin over target. Deeper local indicated if sedation/caudal not used.
  - c. Gripping the central hub (colored), advance the Nimbus MEE down the beam to dorsal sacral bony endpoint.
  - d. Orient the white stripe on main hub of electrode #1 and #2 to face on another. Tines should deflect towards each other to create widest possible lesion.  
Deploy tines. Rotate helical spin collar clockwise until fully advanced. A distinct tactile click will be appreciated with full engagement.
  - e. Check a lateral or contralateral oblique “safety view” to ensure that the tines are on the dorsum of sacrum and not into a sacral foramen / caudal epidural space. A lateral view may be used as an alternative.
  - f. Motor and/or sensory stimulation are not mandatory but available if desired.
  - g. With tines fully deployed, inject local anesthetic of choice if desired.
  - h. Initiate heat cycle (30-second ramp 150 seconds at 90 C.). Note: RF generator needs to be in bi-polar mode.
8. Subsequent lesions
  - a. Retract tines of both electrodes. Remove the most cranial electrode leaving the caudal electrode in place.
  - b. Rotate the caudal electrode 180 degrees to redirect tines. (Some may choose to reposition this electrode 1-3 mm caudal prior to redeploying the tines.)
  - c. Place the electrode that was removed (Electrode #1) approximately 15 mm caudal to electrode that stayed in position (Electrode #2) along a craniocaudal line slightly lateral to the PFSA (see #6).
  - d. Rotate the white stripes on the main hub to again face on another.
  - e. Deploy tines as above.
  - f. Obtain lateral, or contralateral oblique safety view as above.
  - g. Repeat stimulation and local anesthetic injection if desired.
  - h. Repeat lesion heat cycle.
9. Repeat the cranial to caudal “leap-frogging” until desired craniocaudal length of lesion is obtained. *Standard practice supports creating a strip lesion from sacral ala to the level of S3. Some practitioners omit the S3 level. The extent of lesion is at the discretion of the practitioner. Note: In the event of L5/S1 fusion the cranial aspect of the lesion should start cranial to the S1 PFSA as allowed by post operative anatomy.*



**Figure 7** - Continuum technique. First electrode pair - electrode #1 placed at base of S1 superior articular process. Electrode #2 is placed ~15 mm caudal along a line ≤10 mm lateral to the PFSA.



**Figure 8** - Ipsilateral oblique view of first electrode pair.



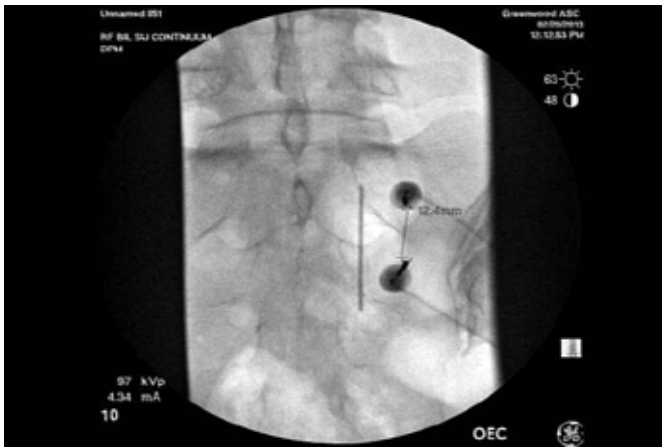


Figure 9 - Second electrode rotated to direct tines caudal. First electrode is placed ~15 mm caudal to second along line running  $\leq 10$  mm lateral to PFSA.

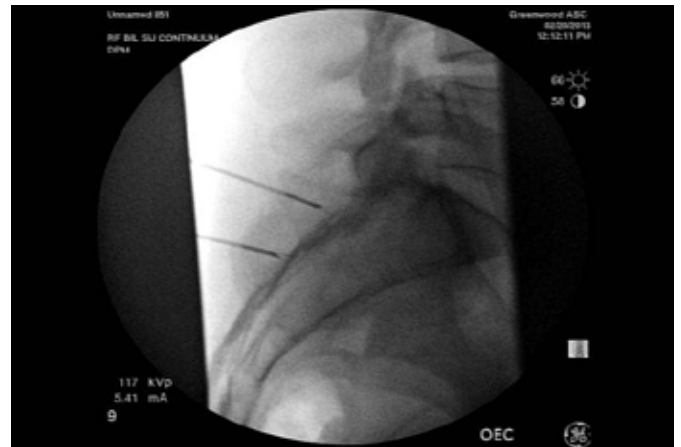


Figure 10 - Lateral view electrode pair.

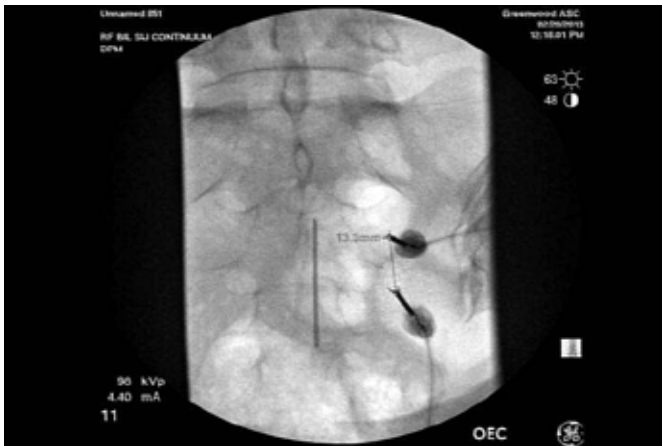


Figure 11 - Electrode #2 positioned ~15 mm caudal to electrode #1 continuing along the line running  $\leq 10$  mm lateral to PFSA.

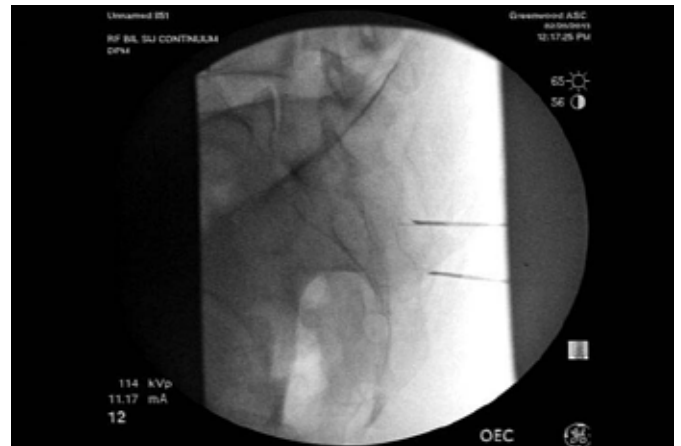


Figure 12 - Representative contralateral safety view showing electrodes on dorsal aspect of sacrum Tines deployed directed toward the paired electrode.

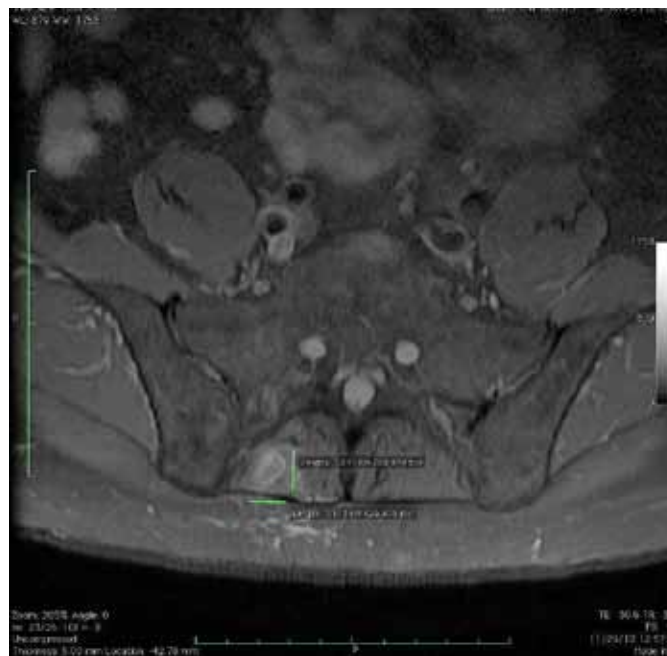

Figure 5 - Representative sacral axial section demonstrating tissue change two weeks after continuum. Lesion in-vivo conforms to ex-vivo prediction.

## LUMBAR MEDIAL BRANCH NEUROTOMY

**BACKGROUND:** RF medial branch thermal neurotomy for proven and recalcitrant lumbar zygapophysial joint pain is a very common neuroablative procedure performed in pain management practices. The RF electrode conventionally used for this procedure is an 18 – 20 gauge single lumen monopolar cannula. The lesion produced by this electrode requires placing the active tip of the electrode parallel and adjacent to the medial branch or dorsal ramus to achieve the desired length of neurotomy. Even if the ideal angle of incidence is accomplished, a challenging task in the most experienced of hands, multiple lesions are required to create a lesion matrix sufficient to ensure disruption of the pain-transmitting pathway. Over the past decades extensive efforts have been made to develop and teach techniques to compensate for the limitations of the traditional electrode technology. These techniques are time and x-ray exposure-intensive, and may be impossible in obese patients or those with advanced arthropathy or abnormal anatomy.

The Nimbus MEE is a fundamental improvement in electrode technology. By design, Nimbus will create a lesion of such size and shape that a straightforward “down-the-beam” approach results in the desired neurotomy. The Nimbus MEE may be used with the classic “pillar view” technique, but offers the additional flexibility of a “down-the-beam” approach fashioned after the standard medial branch block technique familiar to all practitioners.

## PROCEDURE

### DOWN-THE-BEAM TECHNIQUE

#### L1-L4 Medial Branches

1. Identify segment of interest and align superior endplate (e.g., superior endplate of L4 aligned for lesioning of the L3 MB on the L4 transverse process).
2. Rotate fluoroscopy 15-30 degrees ipsilateral oblique to visualize the pedicle shadow and juncture of superior articular process (SAP) with the transverse process. A minimal amount of rotation will ensure the active tip rests adjacent to SAP. In cases of arthropathy more rotation will be needed.
3. Identify a desired target position at the mid of the base of SAP or slightly cranial. In a more caudal position the mamillo-accessory ligament may protect the medial branch from lesion.
4. Infiltrate skin and deep tissues with local anesthetic.
5. Gripping the central hub (colored), advance the cannula over bone target “down the beam” until bony contact.
6. Return to AP to confirm placement at the juncture of the SAP and TP (ensure that cannula tip is sufficiently medial).
7. Obtain a caudocranial decline view adequate to visualize the tip of tip of central cannula at base of SAP in sulcus between SAP/TP.
8. Orient the cannula to project tines away from the midline. (Directional stripe on main hub will point 90 degrees away from spine.)
9. Rotate helical spin collar clockwise until fully advanced. A distinct tactile click will be appreciated with full engagement.

*Continued on next page.*

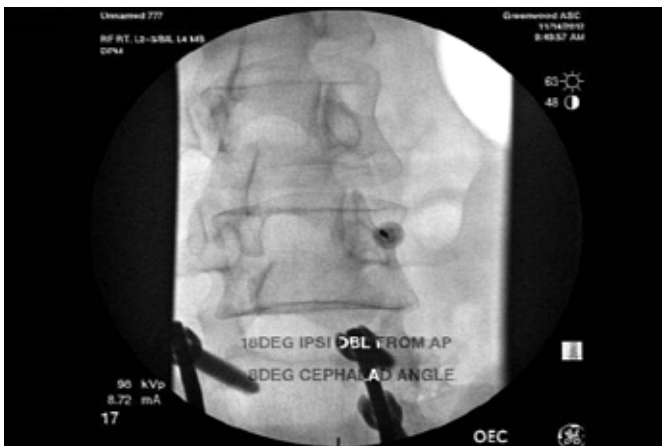


Figure 13 - Down the beam approach lumbar medial branch neurotomy.

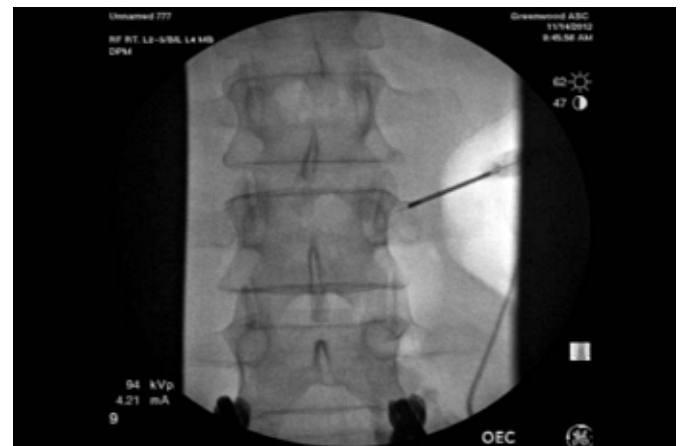


Figure 14 - AD view confirming active tip placement at medial aspect of transverse process.

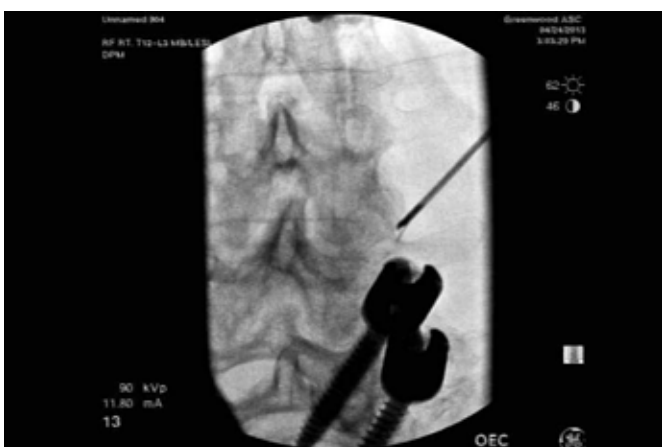

Figure 15 - Caudal decline view to visualize active tip in sulcus.

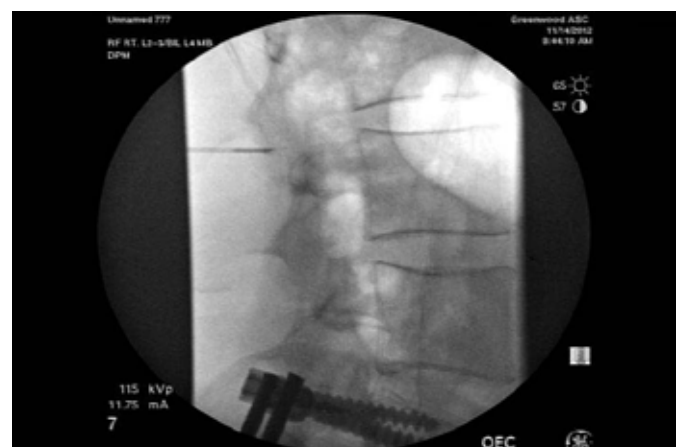


Figure 16 - Lateral view, tines deployed - posterior to neural foramen.

10. Alternative technique can deploy tines toward the SAP. This approach may be useful in cases of z-joint arthropathy with enlarged mammillary process allowing lesion to be directed into sulcus.
  - a. The directional heating bias of the electrode is intended to provide the operator with the ability to fine-tune target coverage and minimize unnecessary collateral tissue injury.
  - b. If device needs to be repositioned tines must always be retracted fully before cannula is manipulated.
11. Check AP image to confirm tines are deployed at base of SAP.
12. Check lateral image with tines deployed. Tines should be at or slightly posterior to the coronal zygapophysial joint lucency. Tines must be dorsal to neural foramen.
13. Motor stimulation: a 2 Hz frequency at 1.5 - 2.0 volts is recommended to rule out ventral ramus activation (absent radicular fasciculations).
14. With tines fully deployed, inject local anesthetic if desired.
15. Recommended heat cycle: 30-second ramp to 80 C maintained for 80 seconds.
16. Retract tines and remove cannula.

## L5 Dorsal Ramus

1. Obtain AP view through the L5/S1 disc space.
2. Rotate ipsilateral oblique or ipsilateral oblique combined with caudal decline to optimize visualization of groove at the base of the S1 SAP.
3. Starting medial to the iliac crest shadow and over groove advance the cannula to the base of the S1 SAP.
4. Slide cannula into groove.
5. Adjust cranial placement using AP view through L5/S1 disc, advancing active tip to cranial edge of sacral ala.
6. Rotate helical spin collar clockwise until fully advanced. A distinct tactile click will be appreciated with full engagement. In general tines are positioned along sacral ala to account for any lateral variability in primary location of the L5 dorsal ramus.
  - a. The directional heating bias of the electrode is intended to provide the operator with the ability to fine-tune target coverage and minimize unnecessary collateral tissue injury.
  - b. If device needs to be repositioned tines must always be retracted fully before cannula is manipulated.
7. Check lateral and adjust as necessary for active tip and tines to be approximately halfway across the L5/S1 facet complex and posterior to the L5/S1 neural foramen.
8. Motor stimulation: a 2 Hz frequency at 1.5 - 2.0 volts is recommended to rule out ventral ramus activation.
9. With tines fully deployed, inject local anesthetic if desired.
10. Recommended heat cycle: 30-second ramp and 80 seconds at 80 C.
11. Consider withdrawing 10 mm and repeating heat cycle.
12. Retract tines and remove cannula.

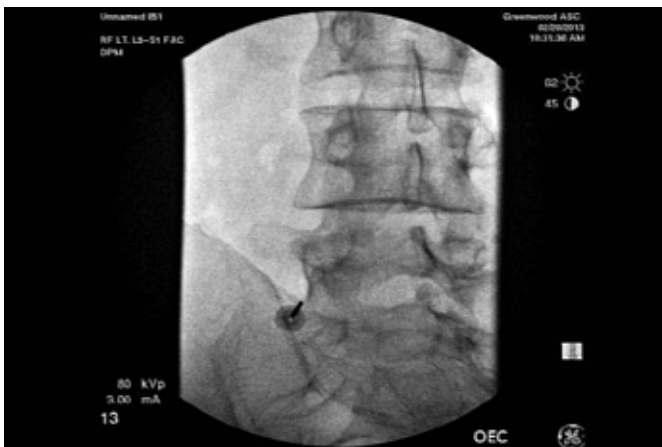


Figure 17 - L5 dorsal ramus - initial cannula trajectory using slight oblique rotation with caudal decline.

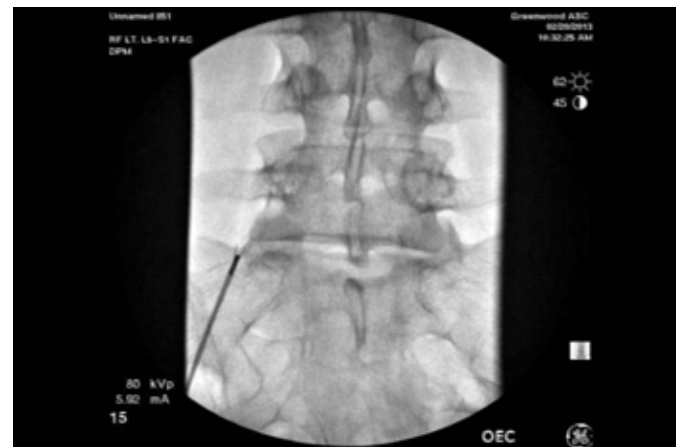

Figure 18 - AP L5, showing active tip in the L5 dorsal ramus groove.

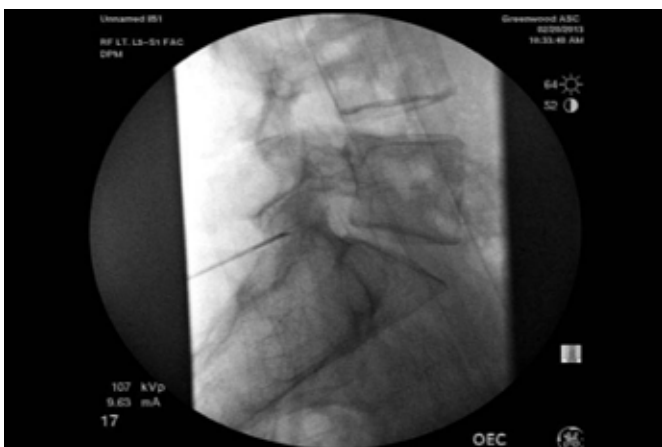


Figure 19 - Lateral view L5 dorsal ramus. Active tip/tines posterior to neural foramen.



## THORACIC MEDIAL BRANCH NEUROTOMY

**BACKGROUND:** The thoracic zygapophysial joint is a common, but frequently overlooked, thoracic spinal pain generator. These structures have been reported to account for up to 48% of chronic thoracic spinal pain. Although the innervation of the joint has been described, and diagnostic block techniques validated, sparse literature exists on thoracic RF medial branch neurotomy. A challenge, and obstacle to appropriate adoption of RF for this indication, is the extreme variability of the T5-8 medial branch locations. Many practitioners are appropriately reluctant to accept the increased risks of a thoracic procedure absent a reliable, safe, efficient, and effective technique. Large volume RF lesions created by an internally-cooled RF electrode have been studied. This device used with simple and safe technique will produce the necessary lesion size for reliable coagulation of thoracic medial branches including the T5-8 medial branches “floating” in the intertransverse space. The Nimbus MEE offers a comparable large volume lesion in a simplified, more economical electrode alternative.

### PROCEDURE

1. Identify target by counting from T1 and T12.
2. Obtain segmental AP image and visualize the most superior lateral corner of the transverse process associated with target medial branch.
3. Consider slight ipsilateral oblique rotation of the C-arm (8-15 degrees), until you see the costotransverse joint lucency (CTJ). In many cases this angle improves visualization/identification of superior lateral transverse process and directs the probe to thoracic anatomic safe zone medial to the pleural cavity, minimizing risk of pneumothorax.
4. Identify skin entry over inferior lateral aspect of transverse process slightly medial to CTJ lucency.
5. Infiltrate skin and deep tissues with local anesthetic.
6. Gripping the central hub (colored), advance cannula over bone starting at the inferior lateral aspect of the TP advancing cannula to superior lateral transverse process. This cannula navigation angle is very close to “down the beam” with slight cranial angulation.
7. Gently touch bone.
8. Rotate C-arm to the contralateral side (15-20 degrees) until the targeted TP is visualized as elongated (Pinocchio view). The position of the cannula tip relative to the superior lateral corner of the TP is easily identified.
9. Position cannula tip at superior lateral corner of TP.
  - a. For T5-8 MBs cautiously advance tip of cannula “sliding” it 3-5 mm cranial into the intertransverse space.
  - b. For T1-4, T9, T10 the cannula tip can stay on bone.
10. Recommended: Orient the cannula to project tines ventromedially. (Directional stripe on main hub will point ventral towards the patient’s back.)
  - a. The directional heating bias of the electrode is always intended to provide the operator with the ability to fine-tune target coverage, and minimize unnecessary collateral tissue injury.
  - b. If device needs to be repositioned tines must always be retracted fully before cannula is manipulated.
11. Rotate helical spin collar clockwise until fully advanced. A distinct tactile click will be appreciated with full engagement. Tines are deployed at this point.
12. Check AP, and lateral x-ray views. The lateral view is useful only to rule out grossly ventral placement.
13. Motor stimulation: at 2 Hz frequency at 1.5 - 2.0 volts is recommended to rule out ventral ramus activation (absent radicular fasciculations).
14. With tines fully deployed, inject local anesthetic if desired.
15. Recommended heat cycle: 30-second ramp to 80 C maintained for 80 seconds.
16. Retract tines fully and remove cannula.

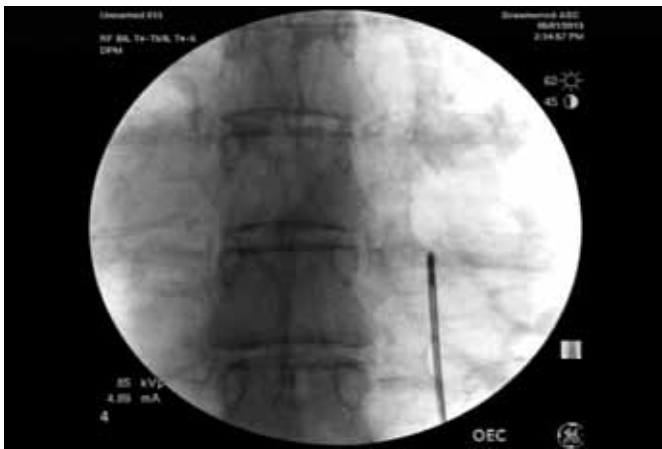


Figure 20 - Thoracic medial branch neurotomy. Active tip positioned at the superior and lateral corner of target transverse process.

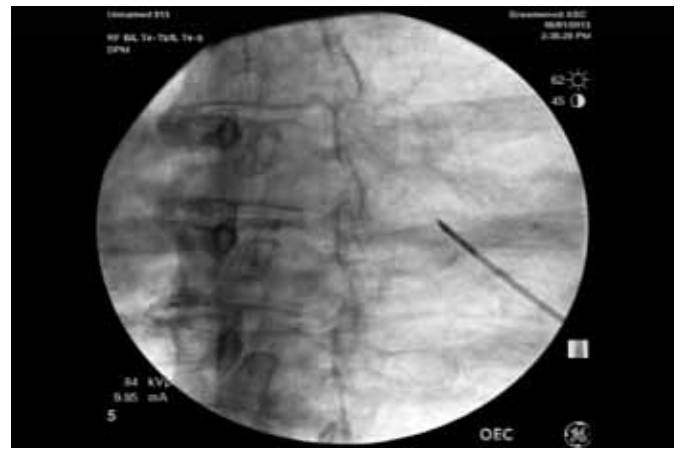


Figure 21 - Contralateral "Pinocchio" view showing elongate transverse process.

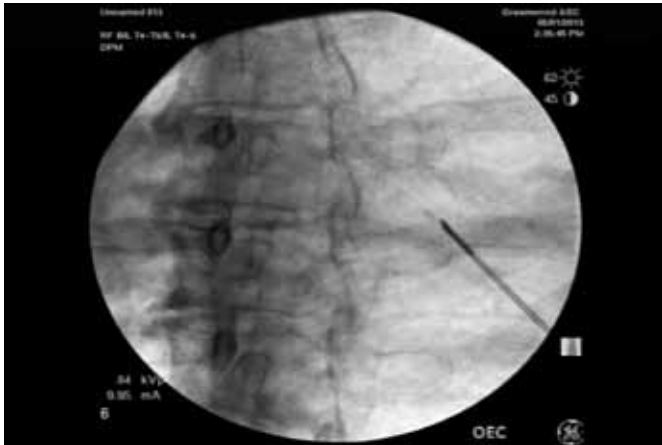


Figure 22 - "Pinocchio" view, tines extended.

## CERVICAL MEDIAL BRANCH NEUROTOMY

**BACKGROUND:** The science supporting therapeutic cervical radiofrequency medial branch neurotomy is prodigious. This intervention, when performed on conscientiously selected patients using scrupulous technique, results in profound pain relief, functional improvement, and decreased analgesic requirement. To fully encompass the anatomic variation inherent in cervical zygapophysial joint innervation and provide durable pain relief large gauge RF electrodes have been recommended. The design of the Nimbus MEE and resulting lesion geometry may be particularly useful for this indication. Relative to the conventional 16 gauge “Ray” electrode a larger volume of tissue is treated per heat cycle thus decreasing the need for active tip repositioning while accomplishing the same lesion. The objective is a safer, less traumatic, more efficient procedure for both the practitioner and patient.

### PROCEDURE

1. Patient is prone with head neutral or slightly rotated away from the targeted side.
2. Target levels are identified with AP imaging. Craniocaudal adjustments are used to optimize convexity of the lateral aspect of the C2/3 joint, and concavity (waist) of the articular pillar at lower levels. At C6 and C7 the target groove is cranial based on the bony anatomy, which is typically more variable.
3. A skin entry point is identified slightly lateral, and inferior to the bony target and infiltrated with local anesthetic.

### Third Occipital Nerve (TON) / C3

- Target is the lateral aspect of the C2/3 joint and lateral mass of C3. Overlapping anatomy dictates treating the TON and C3 MB collectively.
- Gripping the central hub (colored), advance cannula to a bony endpoint at the most dorsal and lateral aspect of the C2/3 z-joint complex joint lucency.
- Obtain lateral image and advance cannula ventrally to slip across the lateral aspect of the joint.
- With the tip of central cannula near ventral margin of the C2/3 z-joint, orient the cannula to project tines toward the midline. (Directional stripe on main hub will point directly toward spine.)
- Rotate helical spin collar clockwise until fully advanced. A distinct tactile click will be appreciated with full engagement. Tines are deployed at this point.
  - The central cannula may have to be passed slightly ventral to easily deploy tines, then may be withdrawn to place tines in desired position. The cannula should not be advanced significantly with the tines deployed.
- Optimal initial position shows tines “straddling” the joint lucency immediately posterior to foramen. Anterior-posterior (AP), lateral, and contralateral oblique (foraminal) views should be obtained for confirmation of position.
- Stimulation protocols may be performed.
- With tines fully deployed, inject local anesthetic if desired.
- Recommended heat cycle: 30-second ramp to 80 C maintained for 80 seconds.
  - Based on anatomic factors and craniocaudal height of C3 foramen additional TON lesions may be placed at a position above and below C2/3 joint line. Ideal separation of one lesion width.
- Tines are fully retracted and cannula is repositioned caudally near mid position on the C3 articular pillar.
- Heating cycle is repeated.
- Retract tines fully and remove cannula.

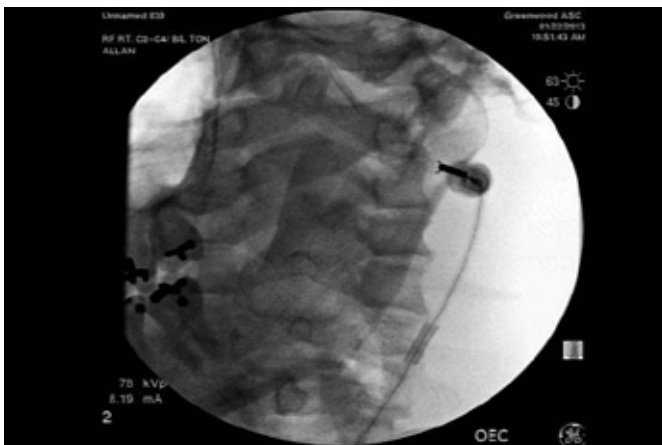


Figure 24 - Third occipital nerve (TON) AP View at 2/3 lateral joint lucency.

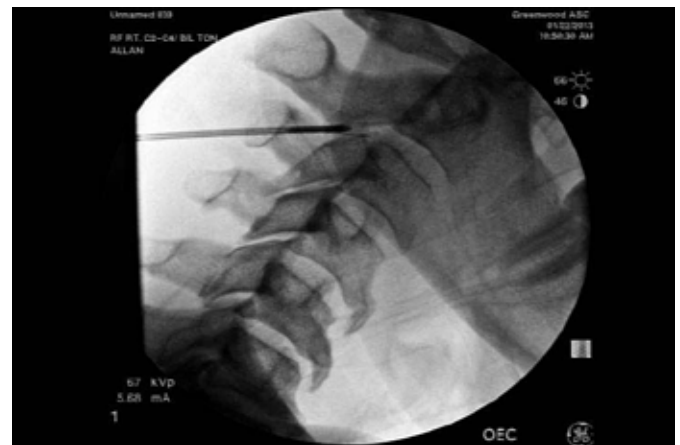

Figure 25 - Lateral view TON.

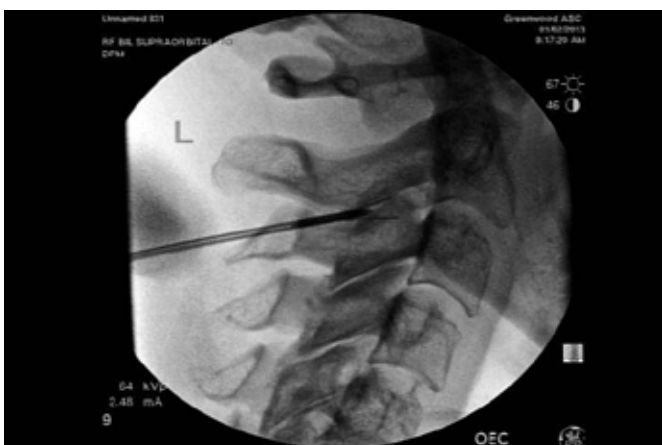

Figure 26 - Lateral view TON.

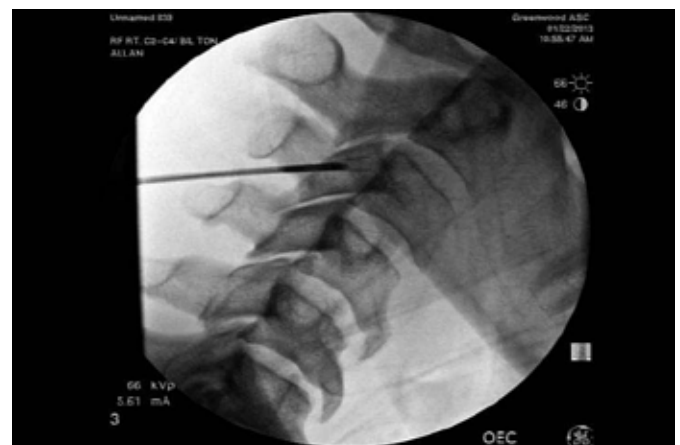

Figure 27 - Lateral view. Lateral aspect C3 articular pillar. Low position TON/C3 medial branch.

## C4, C5

- a. Target is the concavity at the waist of the respective articular pillars.
- b. Gripping the central hub (colored), advance cannula to a bony endpoint at the most dorsal and lateral aspect at the waist of the articular pillar.
- c. Under lateral imaging, advance central cannula to ventral margin of articular pillar.
- d. With the tip of central cannula near ventral margin of the articular pillar the cannula to project tines toward the midline. (Directional stripe on main hub will point directly toward spine).
- e. Rotate helical spin collar clockwise until fully advanced. A distinct tactile click will be appreciated with full engagement. Tines are deployed at this point.
  1. The central cannula may have to be passed slightly ventral to easily deploy tines, then may be withdrawn to place tines in desired position. The cannula should not be advanced significantly with the tines deployed.
- f. On lateral image tines should be centrally positioned on the lateral mass with tines dorsal to neural foramen (slightly cranial to mid-position for C4, true mid position for C5 is optimal). Motor stimulation: a 2 Hz frequency at 1.5 volts is recommended to rule out ventral ramus activation (absent radicular fasciculations).
- g. Motor stimulation: a 2 Hz frequency at 1.5 volts is recommended to rule out ventral ramus activation (absent radicular fasciculations). With tines fully deployed local anesthetic may be injected prior to lesion.
- h. With tines fully deployed, local anesthetic may be injected if desired.
- i. Recommended heat cycle: 30-second ramp to 80 C maintained for 80 seconds.
- j. Retract tines fully and remove cannula.

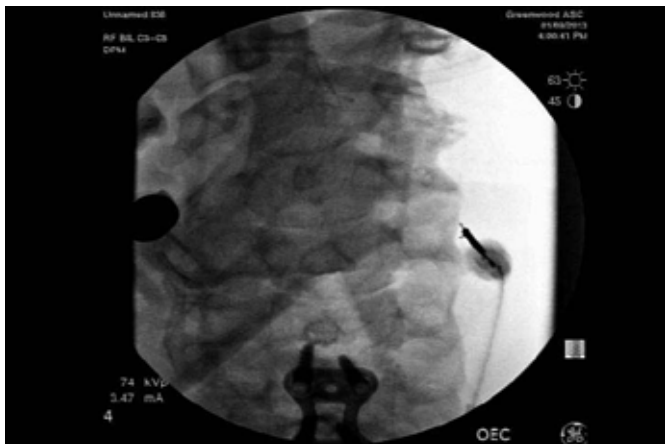


Figure 28 - AP C4 medial branch tines deployed along lateral mass.

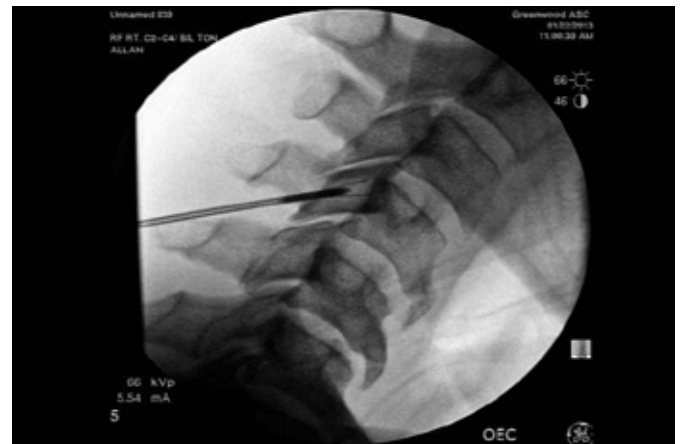

Figure 29 - Lateral view. C4 medial branch target.



## C6, C7

- a. C6 target coverage for tines is between lateral concavity and cranially along SAP.
- b. C7 target coverage for tines is typically high on the articular pillar: tines will straddle the C6/7 joint lucency.
  - 1. Consider second lesion more laterally along the transverse process for patients where this structure is prominent.
- c. Contralateral oblique view may be useful to confirm tines are optimally positioned.
- d. Other technical aspects unchanged.

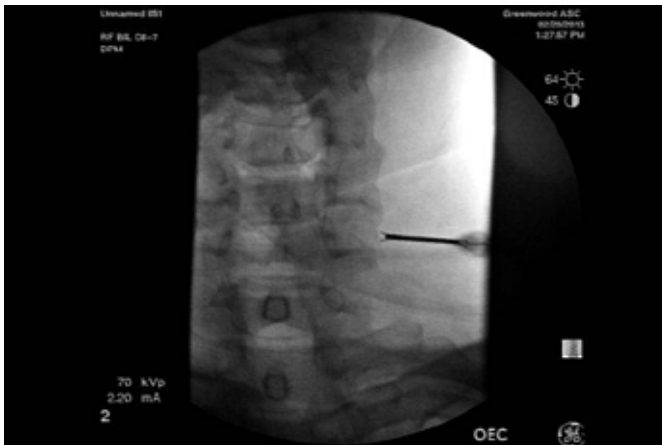


Figure 30 - AP view. C6 medial branch target.

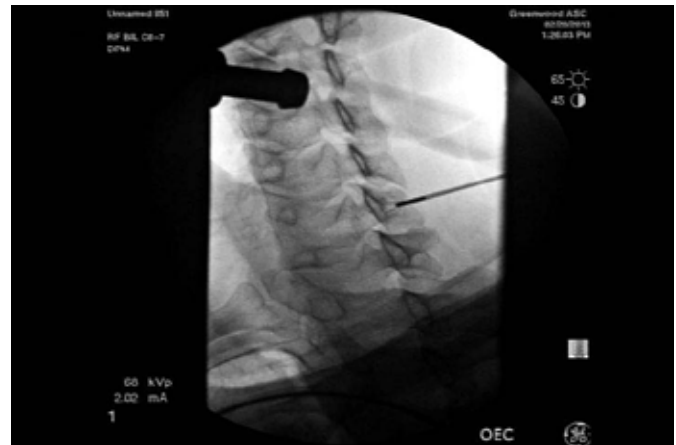


Figure 31 - Contralateral oblique view. C6 medial branch target.

## C8

- e. Target is superior lateral corner of T1 transverse process.
- f. Skin entry is approximately mid position on the T1 transverse process.
- g. Angle superior and lateral staying over bone.
- h. Contact superior lateral corner of T1.
- i. Adjust tip of cannula using lateral or contralateral oblique image.
- j. Deploy tines to straddle the corner of TP (ventral projection of tines - the directional marker on the hub will be in a ventral position, facing transverse process).
- k. Other technical aspects unchanged.

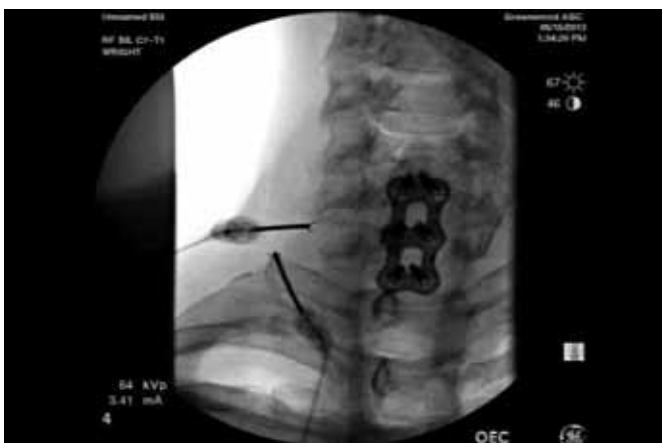

Figure 32 - AP view. C7 and T1 medial branch targets.

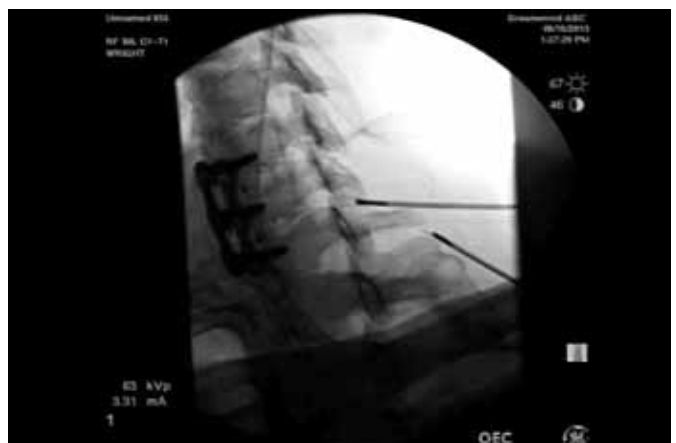
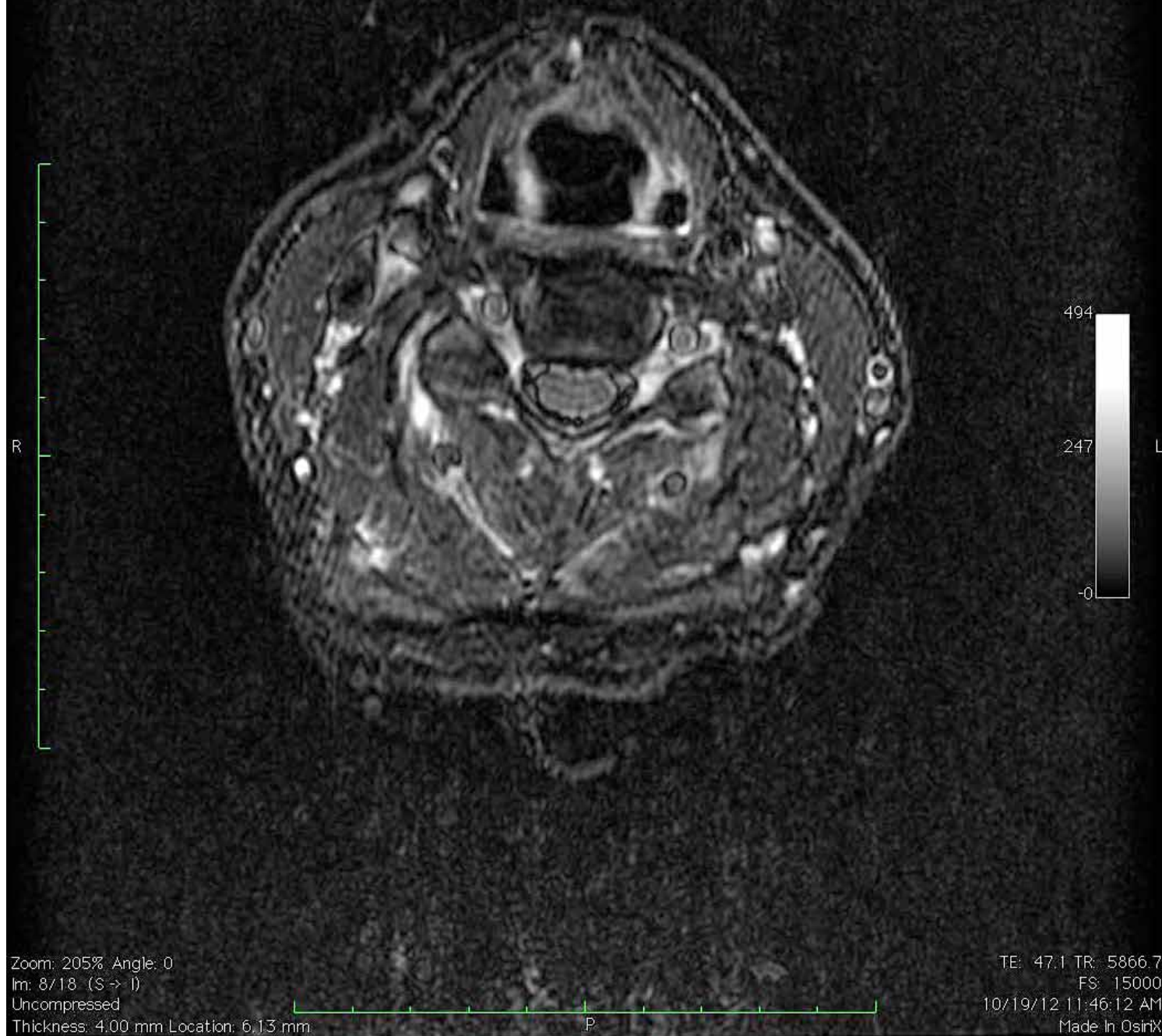
Figure 33 - Contralateral oblique. C7 and T1 medial branch targets.

Image size: 512 x 512  
View size: 1051 x 1051  
WL: 247 WW: 495

A

SD111240833 ( 58 y, 58 y )  
-- SC:AX STR  
27803  
108



**Figure 34** - Representative axial view cervical spine demonstrating tissue change two weeks following C4 - C6 medial branch neurotomy. RF-treated tissue covering lateral aspect of articular pillar encompassing target nerve territory.

## SYMPATHETIC NERVOUS SYSTEM

*BACKGROUND:* Interruption of the sympathetic nervous system may be useful to treat sympathetically mediated pain syndromes. Anesthetic blockade of the sympathetic nervous system has been used for nearly a century to diagnose and treat patients presenting with regional, continuous severe pain associated with disproportionate sensitivity to touch (hyperalgesia/allodynia).

When prolonged sympatholysis is desired as part of a global treatment program then RF lesioning of the sympathetic chain may be considered. The sympathetic chain travels in a craniocaudal direction along the lateral to anterolateral aspect of the vertebral column allowing only relatively perpendicular placement of the active tip relative to the target anatomy. The Nimbus MEE lesion geometry is well suited for this approach, producing the necessary 10 mm craniocaudal lesion width from the perpendicular approach with each lesioning cycle.

*Continued on next page.*

## THORACIC SYMPATHECTOMY

### PROCEDURE

1. Patient positioned prone.
2. Identify T2, and T3 vertebral levels.
3. Adjust x-ray cephalad until the transverse process of the T3 vertebrae is superimposed on the neck of the rib, and the intertransverse space between T2, and T3 is opened.
4. Rotate x-ray slowly toward the side of the target watching for the costotransverse and costovertebral joints to be come nearly superimposed. The neck of the rib should be seen almost “end-on” with this rotation.
5. Identify a skin entry point slightly cephalad to the transverse process of T3, and slightly lateral to the vertebral body shadow.
6. Gripping the central hub (colored), advance the cannula in a down-the-beam fashion aiming at the lateral aspect of the T2 vertebral body.
7. Once bony contact is gently made rotate x-ray beam to lateral image. This view is to determine relative dorsal to ventral placement of the active tip with the target being halfway across the T2 vertebral body.
8. Advance cannula cautiously until tip of cannula is approximately halfway across the vertebral body shadow. If small amounts of adjustment are required maintain lateral position, if more extensive navigation is required return to the starting posterior oblique view.
9. A cannula navigated in a plane medial and parallel to the neck of the rib, and lateral to the vertebral body shadow will be directed into the thoracic “safe-zone”. Familiarity with this anatomical concept is mandatory to avoid pneumothorax and safely accomplish this procedure. If the practitioner does not have intuitive familiarity with the concept of the thoracic “safe-zone” additional education is necessary prior to performing this procedure.
10. With the tip of central cannula near mid position on the lateral aspect of the T2 vertebrae orient the cannula to project tines toward the midline. (Directional stripe on main hub will point directly toward spine.)
11. Rotate helical spin collar clockwise until fully advanced. A distinct tactile click will be appreciated with full engagement. Tines are deployed at this point. The central cannula may have to be passed slightly ventral to easily deploy tines, then may be withdrawn to place tines in desired position. The cannula should not be advanced significantly or repositioned with the tines deployed.
12. Perform sensory stimulation at 50 Hz up to 1 V, to reproduce patient’s symptoms, and motor stimulation at 2 Hz and 2 V. No segmental parathesia or motor fasciculations should occur.
13. With tines fully deployed inject local anesthetic if desired.
14. Recommended heat cycle: 30-second ramp to 80 C maintained for 80 seconds.
15. Retract tines fully and remove cannula.

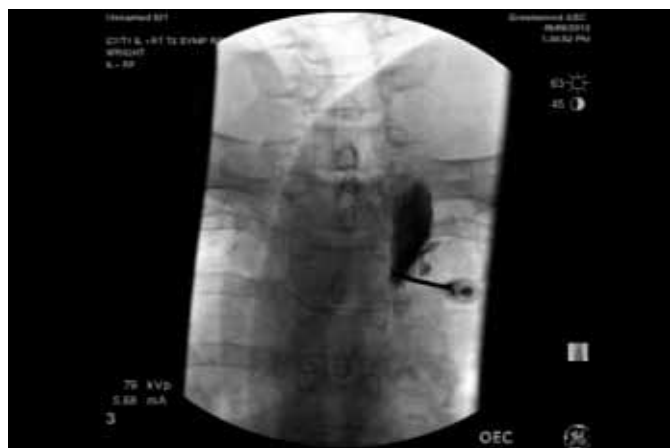

Figure 35 - AP view thoracic sympathectomy.

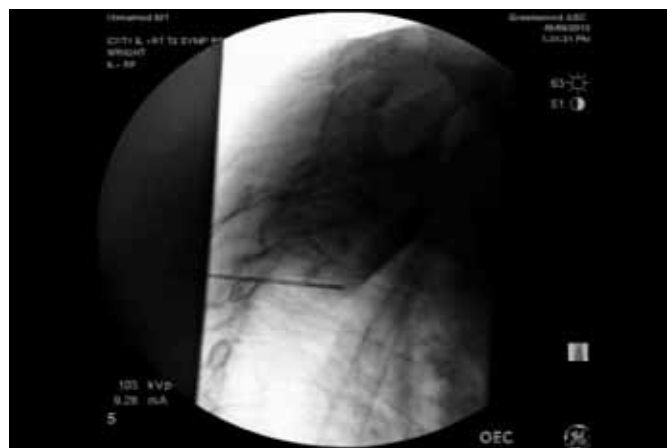

Figure 36 - Lateral view. Thoracic sympathectomy.

## LUMBAR SYMPATHECTOMY

### PROCEDURE

1. Patient prone. (150 mm electrode required)
2. L3 vertebral body identified from AP x-ray imaging.
3. Craniocaudal tilt is adjusted to align the inferior border of the L3 transverse process to intersect the lateral vertebral body shadow at approximately the middle.
4. Rotate the x-ray ipsilateral toward the target side to allow visualization and approach to the ventral aspect of the vertebral body. For the Nimbus MEE this rotation need not be more than 20 degrees. Skin to target distance increases with rotation, as does the possibility of injury to a visceral structure or genitofemoral nerve. Keep rotation to a minimum. The directional offset of the tines when deployed will project the lesion along the ventral lateral vertebra without requiring a more lateral starting position.
5. Identify skin entry slightly inferior to the transverse process and slightly lateral to the vertebral body shadow.
6. Infiltrate skin and deep tissues with local anesthetic.
7. Gripping the central hub (colored), advance cannula. Cannula navigation “down the beam” until gently contacting lateral aspect of vertebral body.
8. Rotate x-ray beam to obtain lateral image.
9. Advance cannula to the ventral 1/3 of vertebral body. The tines should reach the ventral edge.
10. Orient the cannula to project tines toward the midline. (Directional stripe on main hub will point directly toward spine.)
11. Rotate helical spin collar clockwise until fully advanced. A distinct tactile click will be appreciated with full engagement. Tines are deployed at this point. The central cannula may have to be passed slightly ventral to easily deploy tines, then may be withdrawn to place tines in desired position. The cannula should not be advanced significantly or repositioned with tines deployed.
12. Recheck AP image.
13. Sensory stimulation at 50 Hz is performed up to 1 V to ensure that there is no genitofemoral nerve paresthesia. If groin paresthesia is reported the tines should be withdrawn and the cannula advanced to a more anterior and medial position along the vertebra. Motor stimulation at 2 Hz up to 2V should not result in fasciculation.
14. With tines fully deployed, inject local anesthetic if desired.
15. Recommended heat cycle: 30-second ramp to 80 C maintained for 80 seconds.
16. This process may be repeated and the lumbar sympathetic chain disrupted at additional levels based on clinical assessment and results of diagnostic block.
17. Retract tines fully and remove cannula.

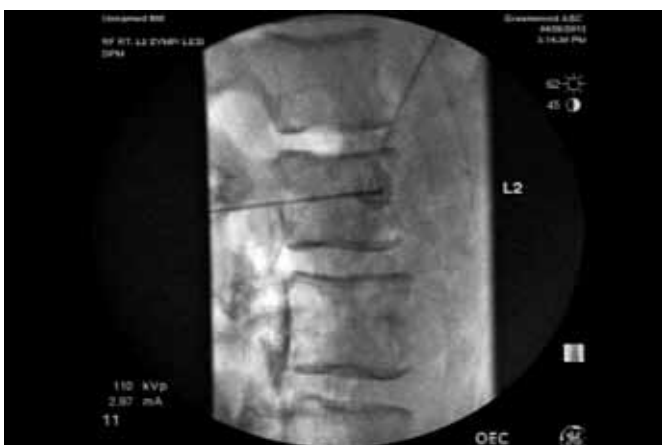

Figure 37 - Lateral view. Thoracic sympathectomy.

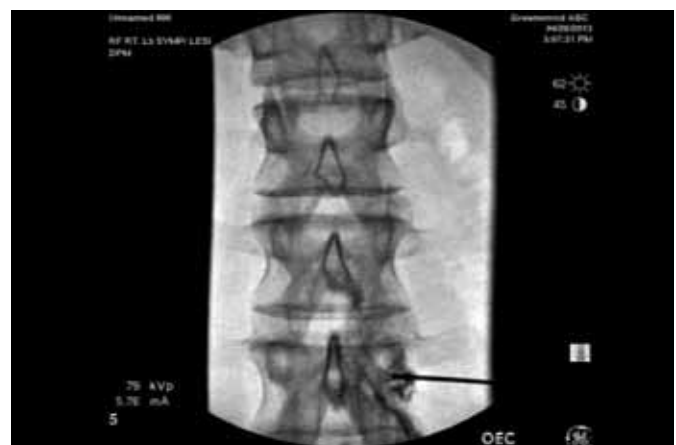

Figure 38 - AP view. Lumbar RF sympathectomy.



## MAJOR PERIPHERAL JOINTS

Non-spinal articular pain is well recognized as a source of chronic pain, impairment in physical functioning, and significant utilization of medical resources. Chronic hip and knee pain have estimated prevalence rates in the 15 - 30% range respectively, increasing with age. Techniques for RF neurotomy targeting the sensory innervation of the hip and knee have been described but are early in their clinical adoption.

Application of RF may represent an important option for patients who do not respond to conservative treatments and have not elected to undergo, or are not candidates, for joint replacement. As with all RF procedures, controlled diagnostic anesthetic blockade of the proposed RF target is essential to qualify a patient for the procedure. In the assessment of patients with hip pain, the practitioner should consider independently blocking the obturator sensory pathway and the femoral sensory pathway to ascertain the relative impact of each on global nociception. The Nimbus MEE produces a lesion of potentially useful size and shape for hip and knee joint denervation procedures.

### OBTURATOR ARTICULAR BRANCHES TO HIP JOINT

#### PROCEDURE

1. Patient is supine.
2. Using ultrasound visualization or by palpation identify the femoral artery and mark the skin. The entry site for the RF cannula should be significantly lateral to this point to prevent injury to femoral vessels or nerve.
3. Under AP view identify the “teardrop” shape representing the caudal end of the anterior lip of the acetabulum. This is the primary target for RF procedure.
  - a. Teardrop shape formed by wall of acetabulum (lateral aspect), all of lesser pelvis (medial aspect), and acetabular notch (inferior). This is the fusion of the ischium and the pubis.
4. In parasagittal plane introduce a 25-gauge 3.5 inch quincke tip needle in a “down-the-beam” fashion onto the caudal-lateral edge of the teardrop. Entry point should be adjusted to be medial to femoral artery location.
  - a. This is the finder needle with the tip positioned at the starting target for RF cannula inserted from oblique entry.

5. X-ray is adjusted 20 degrees cephalad, and rotated ipsilateral until a skin entry point is identified that will allow for down-the-beam navigation of the RF cannula to direct the active tip to the tip of the finder needle, while maintaining a trajectory lateral to the femoral neurovascular bundle. 70 degrees of ipsilateral oblique rotation has been demonstrated to avoid the femoral neurovascular bundle, and provide a predictable margin of safety. The use of ultrasound is recommended as an adjunctive imaging tool. The actual degree of ipsilateral oblique rotation may be reduced based on information from ultrasound.
  - a. With the conventional single lumen monopolar electrode rotation would need to be at least 70 degrees to accomplish parallel adjacent placement of the active tip onto the target nerve. The Nimbus MEE lesion geometry supports effective lesioning from a more perpendicular approach. The only consideration governing x-ray beam rotation is avoiding puncture of the femoral artery or nerve.
6. Infiltrate skin and deep tissues with local anesthetic.
7. Gripping the central hub (colored), advance cannula. Navigate cannula “down the beam” or using a “tunnel” view targeting the tip of the previously placed finder needle.
8. Gently contact bone (caudal lateral edge of teardrop).
9. Active tip should be on bone at the medial inferior acetabular target.
10. Orient the cannula to project tines either anteriorly or posteriorly. Key consideration is to optimize the craniocaudal width of lesion with each heat cycle covering anatomical variability with fewest positions possible.
11. Rotate helical spin collar clockwise until fully advanced. A distinct tactile click will be appreciated with full engagement. Tines are deployed at this point. The cannula should not be advanced significantly or repositioned with the tines deployed.

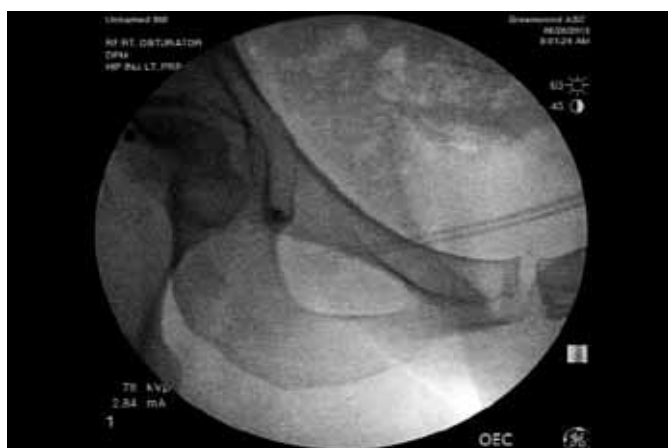

Figure 39 - AP view with finder needle on bone at inferior-medial acetabular margin.

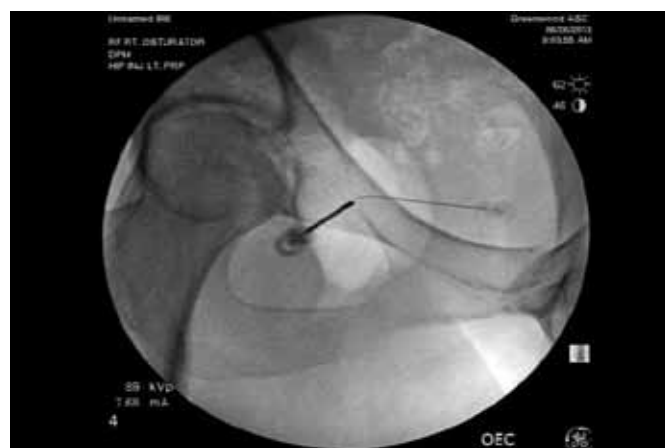

Figure 40- Ipsilateral rotation. RF electrode advanced to target position.

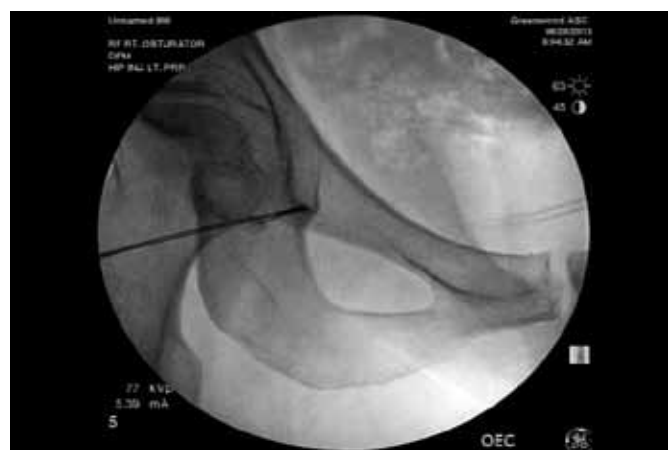

Figure 41 - AP view. Electrode at inferior medial lip of acetabulum along obturator-articular nerve pathway.

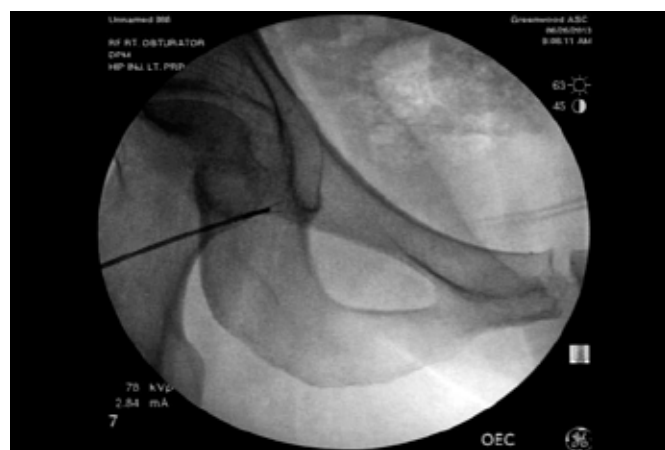
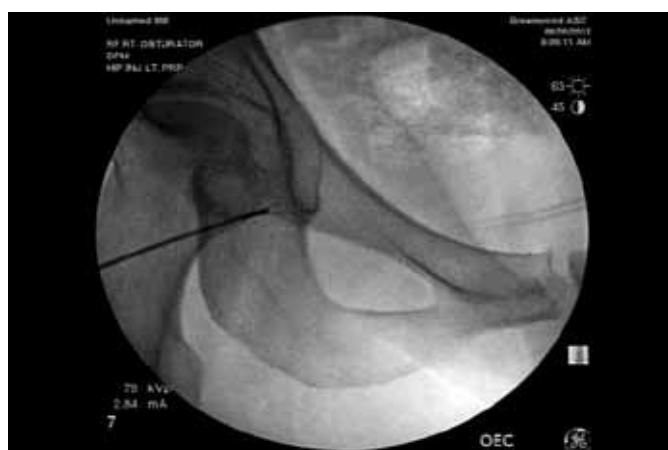
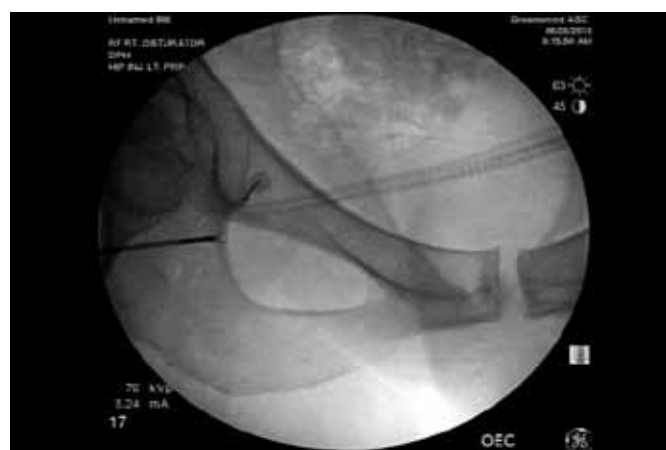
Figure 42 - Electrode at initial lesion position with tines deployed.

12. Tip of tines should always be lateral to the teardrop to minimize risk of coagulating the obturator nerve.
13. Motor stimulation: a 2 Hz frequency at 2.0 volts is recommended to assess proximity to obturator nerve. Fasciculations should not be produced by stimulation. Consider sensory stimulation at 50 Hz up to 1.0 V.
14. With tines fully deployed, inject local anesthetic if desired.
15. Recommended heat cycle: 30-second ramp to 80 C maintained for 80 seconds.
16. Retract tines fully.
17. Withdraw 10 mm and redirect posteriorly onto joint capsule.
18. Repeat stimulation and anesthetic injection.
19. Repeat heat cycle.
20. To completely cover possible anatomic variation in the course of the articular branches the lesion matrix should be extended progressively caudal from immediately inferior to the tear drop target to the juncture of the caudal and medial thirds of the obturator foramen. A total of three to four lesions will create an adequate zone of coagulation.
21. All lesions should be at approximately the depth of the inferior lateral edge of the teardrop (maximum 3-5 mm dorsal) as identified with the first lesion, and tines should be lateral to the obturator foramen. As the lesion matrix is extended caudally the lesions should be moved slightly lateral to further minimize injury to the main obturator nerve.
22. When procedure is concluded, retract tines fully and remove cannula.



**Figure 43** - AP view. Electrode at inferior medial lip of acetabulum along obturator-articular nerve pathway. Withdrawn to increase length of neurotomy.

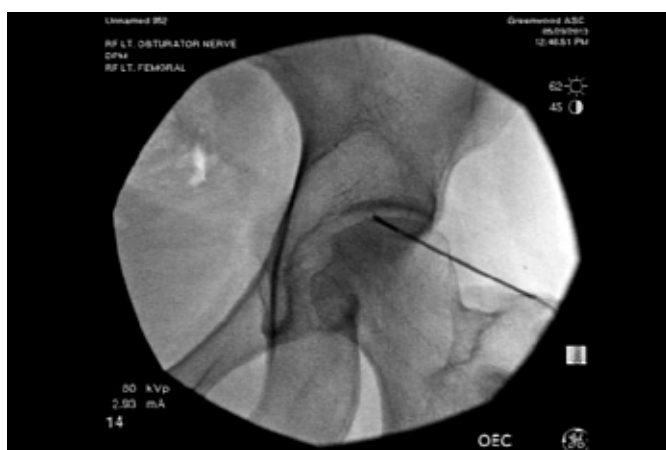

**Figure 44** - Electrode position one lesion width inferior lateral to obturator foramen.

## FEMORAL ARTICULAR BRANCHES

### PROCEDURE

1. Patient is supine.
2. Using AP x-ray imaging, identify a skin entry site over the greater trochanter of the hip at approximately the level of the anterior inferior iliac spine.
3. Local anesthetic if desired.
4. Gripping the central hub (colored), advance cannula. Navigate cannula to the anterolateral aspect of the extra-articular hip joint at a position below the anterior inferior iliac spine.
5. Position cannula tip below the anterior inferior iliac spine near antero-lateral margin of the hip joint.
6. Orient the cannula to project tines either anteriorly or posteriorly. Key consideration is to optimize the craniocaudal width of lesion with each heat cycle, covering anatomical variability with fewest positions possible.
7. Rotate helical spin collar clockwise until fully advanced. A distinct tactile click will be appreciated with full engagement. Tines are deployed at this point. The cannula should not be advanced significantly or repositioned with tines deployed.
8. Motor stimulation: a 2 Hz frequency at 2.0 volts is required to exclude fasciculations for safety. Consider sensory stimulation at 50 Hz up to 1.0 V in a wakeful patient to optimize lesion placement.
9. Local anesthetic if desired.
10. Recommended heat cycle: 30-second ramp to 80 C maintained for 80 seconds.
11. Retract tines fully.
12. Consider two to three additional lesions moving 5 mm caudal from initial position to create a matrix covering the anterolateral margin of the joint.
13. Repeat stimulation and anesthetic injection. Repeat heat cycle.
14. Retract tines fully and remove cannula.



*Figure 45 - Representative initial RF electrode placement for lesion of the femoral articular branches.*

## GENICULAR NERVE ABLATION TO KNEE JOINT

### PROCEDURE

1. Patient positioned supine with pillow under the popliteal fossa.
2. True AP x-ray of the tibiofemoral joint obtained showing open tibiofemoral joint space with equal width interspaces medially and laterally.
3. Three RF targets:
  - a. Superior lateral genicular nerve located at the transition of shaft of femur to lateral epicondyle.
  - b. Superior medial genicular nerve located at the transition of the shaft of femur to medial epicondyle.
  - c. Inferior medial genicular nerve located at the transition of the shaft of the tibia to the medial epicondyle.
4. Infiltrate skin and deep tissues overlying targets with local anesthetic.
5. Gripping the central hub (colored), advance cannula. Navigate cannula in a down-the-beam fashion to contact bone at each of the target sites.
6. Adjust depth under lateral x-ray to approximate placement at mid-shaft of femur and tibia.
7. Perform sensory stimulation at 50 Hz to optimize position. Satisfactory stimulation threshold is 0.6 V. Motor stimulation: a 2 Hz up to 2 V should not elicit fasciculations.
8. Orient the cannula to project tines toward bone.
9. Rotate helical spin collar clockwise until fully advanced. A distinct tactile click will be appreciated with full engagement. Tines are deployed at this point. The cannula should not be advanced significantly or repositioned with tines deployed.
10. Local anesthetic if desired.
11. Recommended heat cycle: 30-second ramp to 80 C maintained for 80 seconds.
12. Retract tines fully and remove cannula.

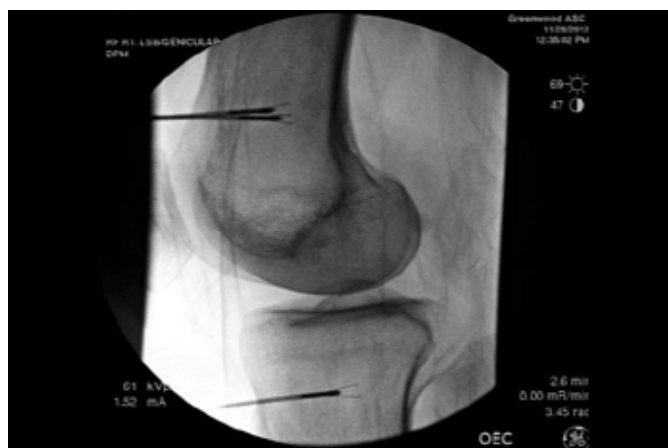


Figure 46- Lateral view of electrodes optimally positioned over genicular targets.

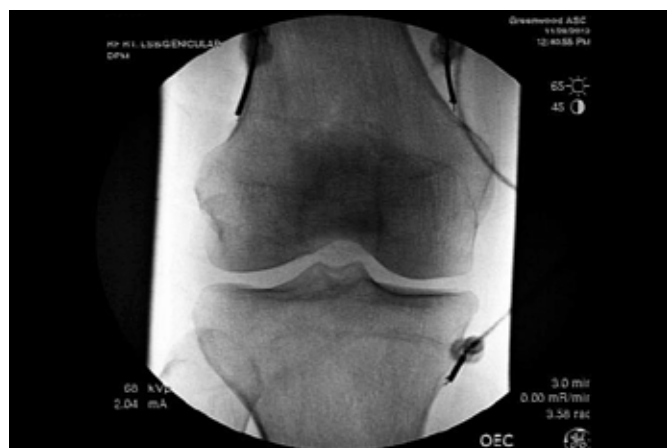

Figure 47 - AP view of electrode optimally positioned over genicular targets.



## READING LIST

### CERVICAL

Bogduk N. The clinical anatomy of the cervical dorsal rami. *Spine (Phila Pa 1976)*1982 Jul-Aug;7(4):319-30.

Aprill C, Bogduk N. The prevalence of cervical zygapophyseal joint pain. A first approximation. *Spine (Phila Pa 1976)*1992 Jul;17(7):744-7.

Lord SM, Barnsley L, Wallis BJ, McDonald GJ, Bogduk N. Percutaneous radio-frequency neurotomy for chronic cervical zygapophyseal-joint pain. *N Engl J Med*1996 Dec 5;335(23):1721-6.

Lord S, McDonald G, N. B. Radiofrequency Neurotomy of the Cervical Medial Branches: A Validated Treatment for Cervical Zygapophysial Joint Pain. *Neurosurgery Quarterly*1998;8(4):288-308.

Govind J, King W, Bailey B, Bogduk N. Radiofrequency neurotomy for the treatment of third occipital headache. *J Neurol Neurosurg Psychiatry*2003 Jan;74(1):88-93.

Husted DS, Orton D, Schofferman J, Kine G. Effectiveness of repeated radiofrequency neurotomy for cervical facet joint pain. *J Spinal Disord Tech*2008 Aug;21(6):406-8.

Macvicar J, Borowczyk JM, Macvicar AM, Loughnan BM, Bogduk N. Cervical medial branch radiofrequency neurotomy in New Zealand. *Pain Med*2012 May;13(5):647-54.

Cooper G, Bailey B, Bogduk N. Cervical zygapophysial joint pain maps. *Pain Med*2007 May-Jun;8(4):344-53.

### THORACIC

Chua WH, Bogduk N. The Surgical Anatomy of Thoracic Facet Denervation. *Acta-Neurochirurgica*1995;136(3-4):140-4.

Wright R.E., Brandt S.A., Allan K.J., Wolfson, J., Dine, A. Cooled Radiofrequency System For The Treatment of Thoracic Facet Joint Pain: The First Prospective Case Series Using A Novel Placement Technique. *Regional Anesthesia and Pain Medicine*2011;36(7 Supplement):E228 - 9.

### LUMBAR

Oudenhoven RC. Paraspinal electromyography following facet rhizotomy. *Spine (Phila Pa 1976)*1977;2:299-304.

Bogduk N, Long DM. The anatomy of the so-called “articular nerves” and their relationship to facet denervation in the treatment of low-back pain. *J Neurosurg*1979 Aug;51(2):172-7.

Bogduk N, Wilson AS, Tynan W. The human lumbar dorsal rami. *J Anat*1982 Mar;134(Pt 2):383-97.

Dreyfuss P, Halbrook B, Pauza K, Joshi A, McLarty J, Bogduk N. Efficacy and validity of radiofrequency neurotomy for chronic lumbar zygapophysial joint pain. *Spine (Phila Pa 1976)*2000 May 15;25(10):1270-7.

Lau P, Mercer S, Govind J, Bogduk N. The surgical anatomy of lumbar medial branch neurotomy (facet denervation). *Pain Med*2004 Sep;5(3):289-98.

Nath S, Nath CA, Pettersson K. Percutaneous lumbar zygapophysial (Facet) joint neurotomy using radiofrequency current, in the management of chronic low back pain: a randomized double-blind trial. *Spine (Phila Pa 1976)*2008 May 20;33(12):1291-7; discussion 8.

Bogduk N, Dreyfuss P, Govind J. A narrative review of lumbar medial branch neurotomy for the treatment of back pain. *Pain Med*2009 Sep;10(6):1035-45.

Smuck M, Crisostomo RA, Trivedi K, Agrawal D. Success of initial and repeated medial branch neurotomy for zygapophysial joint pain: a systematic review. *PM R*2012 Sep;4(9):686-92.

Kapural L, Stojanovic M, Sessler DI, Bensitel T, Zovkic P. Cooled radiofrequency (RF) of L5 dorsal ramus for RF denervation of the sacroiliac joint: technical report. *Pain Med*2010 Jan;11(1):53-7.

Macvicar J, Borowczyk JM, Macvicar AM, Loughnan BM, Bogduk N. Lumbar medial branch radiofrequency neurotomy in New Zealand. *Pain Med*2013 May;14(5):639-45.

## SACROILIAC JOINT

Yin W, Willard F, Carreiro J, Dreyfuss P. Sensory stimulation-guided sacroiliac joint radiofrequency neurotomy: technique based on neuroanatomy of the dorsal sacral plexus. *Spine (Phila Pa 1976)*2003 Oct 15;28(20):2419-25.

Cohen SP, Hurley RW, Buckenmaier CC, 3rd, Kurihara C, Morlando B, Dragovich A. Randomized placebo-controlled study evaluating lateral branch radiofrequency denervation for sacroiliac joint pain. *Anesthesiology*2008 Aug;109(2):279-88.

Dreyfuss P, Henning T, Malladi N, Goldstein B, Bogduk N. The ability of multi-site, multi-depth sacral lateral branch blocks to anesthetize the sacroiliac joint complex. *Pain Med*2009 May-Jun;10(4):679-88.

Mazin DA, Sullivan JP. Lumbar and sacral radiofrequency neurotomy. *Phys Med Rehabil Clin N Am*2010 Nov;21(4):843-50.

Speldewinde GC. Outcomes of percutaneous zygapophysial and sacroiliac joint neurotomy in a community setting. *Pain Med*2011 Feb;12(2):209-18.

Patel N, Gross A, Brown L, Gekht G. A randomized, placebo-controlled study to assess the efficacy of lateral branch neurotomy for chronic sacroiliac joint pain. *Pain Med*2012 Mar;13(3):383-98.

Vleeming A, Schuenke MD, Masi AT, Carreiro JE, Danneels L, Willard FH. The sacroiliac joint: an overview of its anatomy, function and potential clinical implications. *J Anat*2012 Dec;221(6):537-67.

## SYMPATHETIC

Racz GB, Stanton-Hicks M. Lumbar and thoracic sympathetic radiofrequency lesioning in complex regional pain syndrome. *Pain Pract*2002 Sep;2(3):250-6.

## HIP

Fukui S, Nosaka S. Successful relief of hip joint pain by percutaneous radiofrequency nerve thermocoagulation in a patient with contraindications for hip arthroplasty. *J Anesth*2001;15(3):173-5.

Kawaguchi M, Hashizume K, Iwata T, Furuya H. Percutaneous radiofrequency lesioning of sensory branches of the obturator and femoral nerves for the treatment of hip joint pain. *Reg Anesth Pain Med*2001 Nov-Dec;26(6):576-81.

Malik A, Simopolous T, Elkersh M, Aner M, Bajwa ZH. Percutaneous radiofrequency lesioning of sensory branches of the obturator and femoral nerves for the treatment of non-operable hip pain. *Pain Physician*2003 Oct;6(4):499-502.

Locher S, Burmeister H, Bohlen T, Eichenberger U, Stoupis C, Moriggl B, Siebenrock K, Curatolo M. Radiological anatomy of the obturator nerve and its articular branches: basis to develop a method of radiofrequency denervation for hip joint pain. *Pain Med*2008 Apr;9(3):291-8.

Rivera F, Mariconda C, Annaratone G. Percutaneous radiofrequency denervation in patients with contraindications for total hip arthroplasty. *Orthopedics*2012 Mar;35(3):e302-5.

Chaiban G, Paradis T, Atallah J. Use of Ultrasound and Fluoroscopy Guidance in Percutaneous Radiofrequency Lesioning of the Sensory Branches of the Femoral and Obturator Nerves. *Pain Pract*2013 May 9.

## KNEE

Choi WJ, Hwang SJ, Song JG, Leem JG, Kang YU, Park PH, Shin JW. Radiofrequency treatment relieves chronic knee osteoarthritis pain: a double-blind randomized controlled trial. *Pain*2011 Mar;152(3):481-7.



14001 SE First Street | Vancouver, WA 98684 | Toll Free: 1-855-490-PAIN (7246) | [www.rsmedical.com](http://www.rsmedical.com)